

PATIENT

Jaxson Lewin

SPECIES

Canine

BREED

Maltese Mix

SEX

MN

AGE

8 years

WEIGHT

7.3 #

INTERPRETED BY

Remo Lobetti, BVSc,
MMedVet (Med), PhD,
Dipl. ECVIM

IMAGING PERFORMED BY

Lara Wiseman, DVM

HOSPITAL NAME

Heron Lakes Animal
Hospital

REFERRING VET

INVOICE

303088

DATE

7/1/22

PRESENTING CLINICAL SIGNS

History: Mineralization within the gallbladder, syncopal episode vs seizure, new heart murmur.

Physical Examination: N/A.

Urinalysis: N/A.

CBC: N/A.

Serum Biochemistry: N/A.

Radiographic Findings: N/A.

ULTRASONOGRAPHIC EXAMINATION OF THE ABDOMEN

Urinary System

Full urinary bladder with a normal thickness and appearance of the wall. Normal anechoic urine with no sediment or uroliths evident.

Normal trigone area, proximal urethra, and iliac blood vessels.

Normal iliac lymph nodes. Ureters not visualized.

Normal size of left kidney (3 cm), right renomegaly (4.8 cm) as a result of a large cyst (2.9 x 3 cm) in the cranial pole. Both kidneys have an increased echogenic appearance, some loss of cortico-medullary differentiation, and normal pelvis and capsule.

Reproductive System

Small hypoechogenic prostate (1 cm).

Adrenal Glands

Normal shape, echogenic appearance, position, and size. Left 0.44 cm, right 0.48 cm.

Spleen

Normal size (0.9 cm) and echogenic appearance. Smooth homogenous parenchyma, smooth curvi-linear capsule, and normal vasculature. No evidence of inflammatory, neoplastic, infarction, or infiltrative changes noted.

Liver

Normal size, echogenic appearance, and portal markings. Two irregular hypoechogenic parenchymal masses (2 x 2.7 cm, 1.5 x 1.9 cm) in the left lobes. Full gall bladder containing moderate amount of hyperechogenic sediment and small liths. Thickened and hyperechogenic appearance of the gall bladder wall. Normal bile duct (0.2 cm).



PATIENT

Jaxson Lewin

SPECIES

Canine

BREED

Maltese Mix

SEX

MN

AGE

8 years

WEIGHT

7.3 #

INTERPRETED BY

Remo Lobetti, BVSc,
MMedVet (Med), PhD,
Dipl. ECVIM

IMAGING PERFORMED BY

Lara Wiseman, DVM

HOSPITAL NAME

Heron Lakes Animal
Hospital

REFERRING VET

INVOICE

303088

DATE

7/1/22

Gastrointestinal

Normal appearance of the stomach, duodenum, small intestine, and ileo-cecal junction with no loss of layering, normal wall thickness (stomach 0.25 cm, duodenum 0.43 cm, jejunum 0.24 cm) and peristaltic activity, and no distension of the lumen.

Pancreas

Normal size (1 cm) and echogenic appearance. Normal echogenic appearance of the mesentery and fat surrounding the pancreas.

Free Abdomen

No mesenteric lymphadenomegaly.
No ascites.

Irregular mottled echogenic mass (3.8 x 3.8 cm) cranial to the urinary bladder that does not appear to be associated with any organ but could be a lymph node.

ULTRASONOGRAPHIC FINDINGS

Primary findings:

- Hepatic masses.
- Abdominal mass.
- Cholecystitis

Secondary findings:

- Age-related renal changes.
- Renal cyst.

INTERPRETATION OF THE FINDINGS & FURTHER RECOMMENDATIONS

Etiologies for the hepatic masses would be nodular hyperplasia, granulomas, hematomas, and neoplasia.

Etiologies for the abdominal mass would be granuloma, hematoma, and neoplasia.

The appearance of the gall bladder is consistent with cholecystitis.

Further assessment would be 3-view thoracic radiographs and FNA cytology of the hepatic masses and the abdominal mass. Laparotomy should also be considered as it could be both diagnostic and therapeutic.

Specific therapy would be dependent on an etiological diagnosis.



PATIENT

Jaxson Lewin

SPECIES

Canine

BREED

Maltese Mix

SEX

MN

AGE

8 years

WEIGHT

7.3 #

INTERPRETED BY

Remo Lobetti, BVSc,
MMedVet (Med), PhD,
Dipl. ECVIM

IMAGING PERFORMED BY

Lara Wiseman, DVM

HOSPITAL NAME

Heron Lakes Animal
Hospital

REFERRING VET

INVOICE

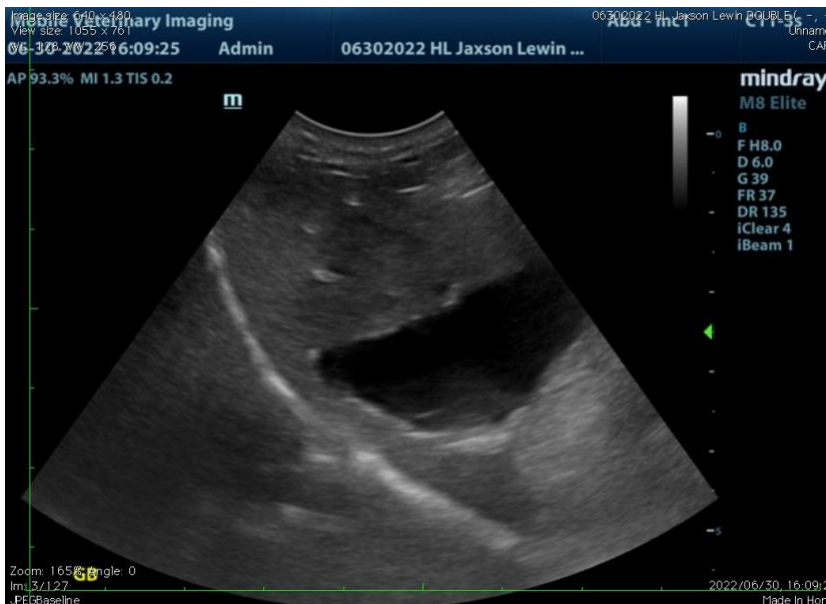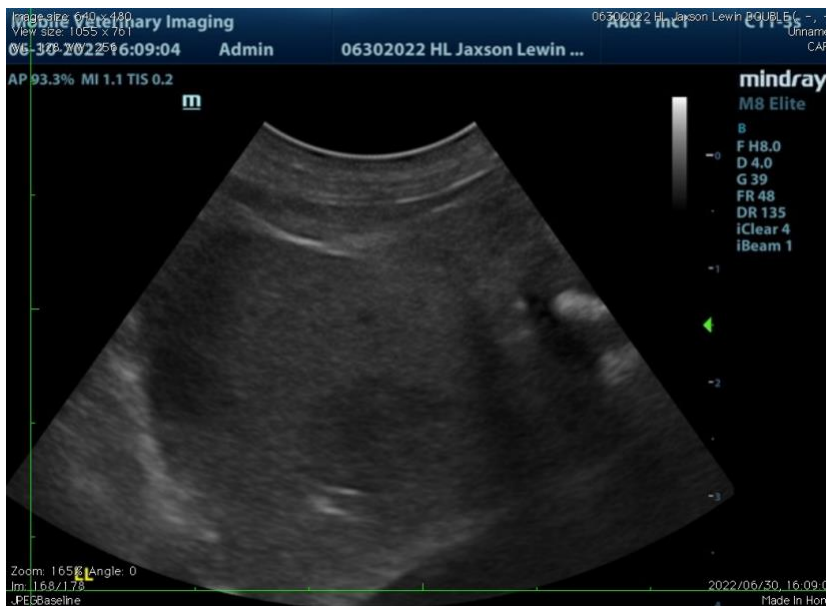303088

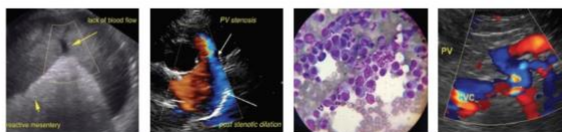
DATE

7/1/22

IMAGES

Liver





PATIENT

Jaxson Lewin

SPECIES

Canine

BREED

Maltese Mix

SEX

MN

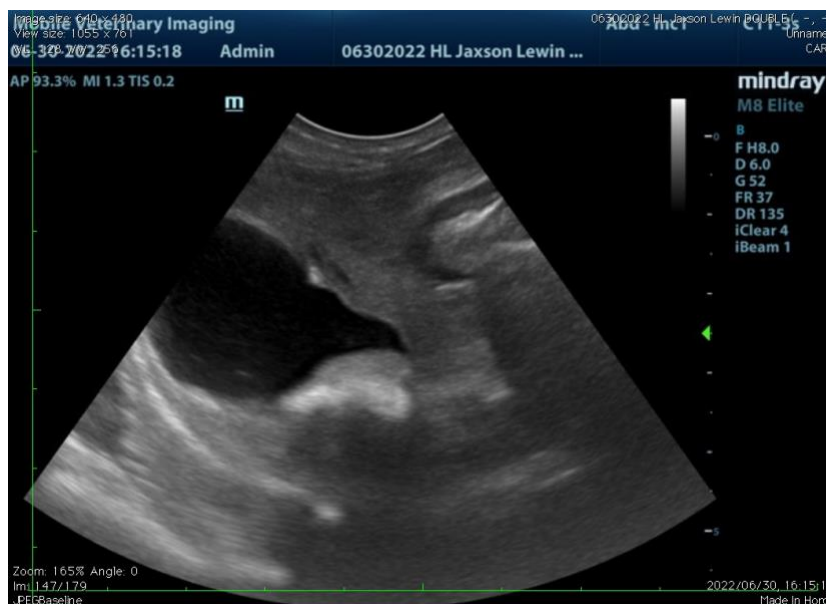AGE

8 years

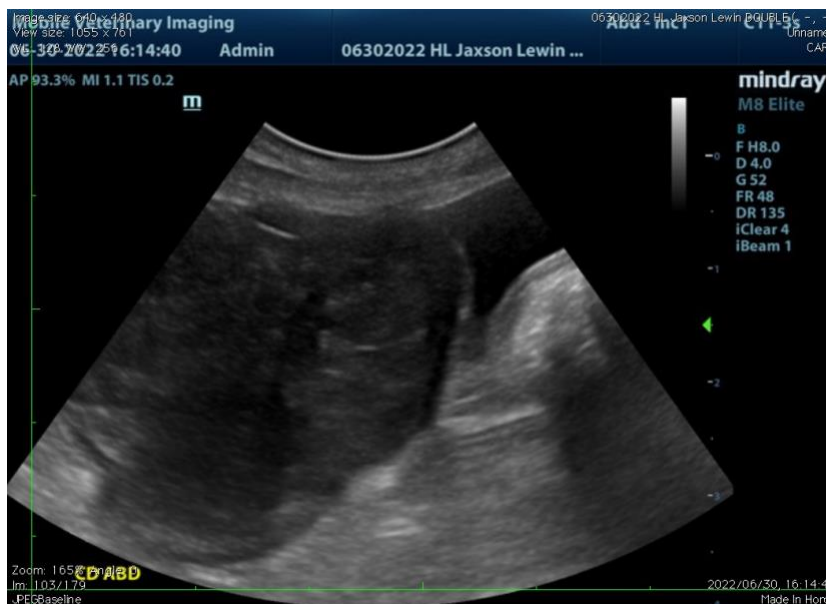WEIGHT

7.3 #

Gall bladder



Mass



INTERPRETED BY

Remo Lobetti, BVSc,
 MMedVet (Med), PhD,
 Dipl. ECVIM

IMAGING PERFORMED BY

Lara Wiseman, DVM

HOSPITAL NAME

Heron Lakes Animal
 Hospital

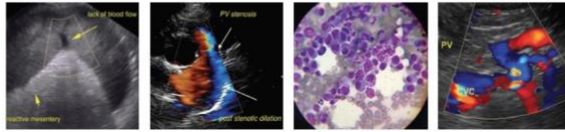
REFERRING VET

INVOICE

303088

DATE

7/1/22



PATIENT

Jaxson Lewin

SPECIES

Canine

BREED

Maltese Mix

SEX

MN

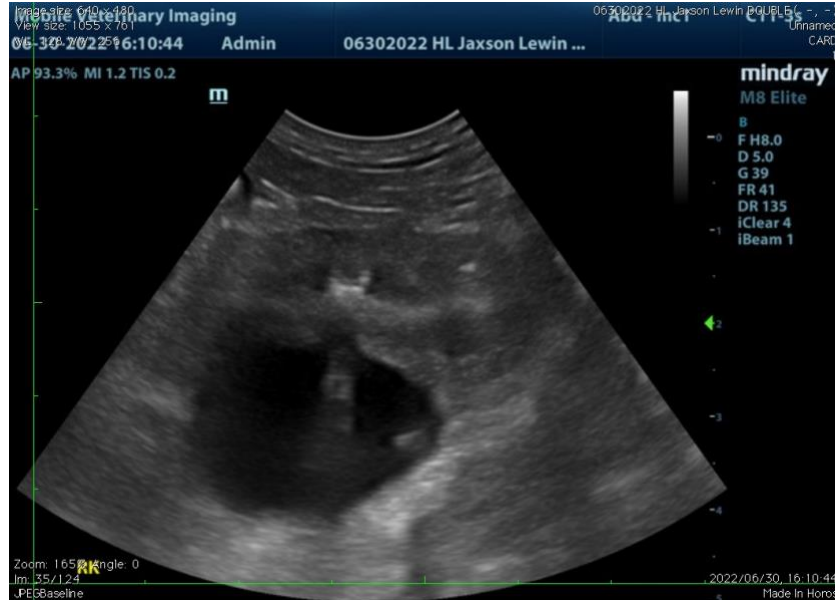AGE

8 years

WEIGHT

7.3 #

Right kidney



INTERPRETED BY

Remo Lobetti, BVSc,
MMedVet (Med), PhD,
Dipl. ECVIM

The information and recommendations provided are based on the images presented by the referring veterinarian. No evaluation can be communicated regarding pathology that was not visible in the image/video clips provided.

Thank you for this referral. If the clinical or image interpretation does not parallel your findings or if I can be of any further assistance please contact me.

IMAGING PERFORMED BY

Lara Wiseman, DVM

Remo Lobetti, BVSc, MMedVet (Med), PhD, Dipl. ECVIM (Internal Medicine)
rlobetti@mweb.co.za

HOSPITAL NAME

Heron Lakes Animal
Hospital

REFERRING VET

INVOICE

303088

DATE

7/1/22